

# APPENDICULAR SKELETON LAB UPPER LIMB VIDEO RECORDING LINKS AND TERMINOLOGY LIST

Dr. Lisa Brinn



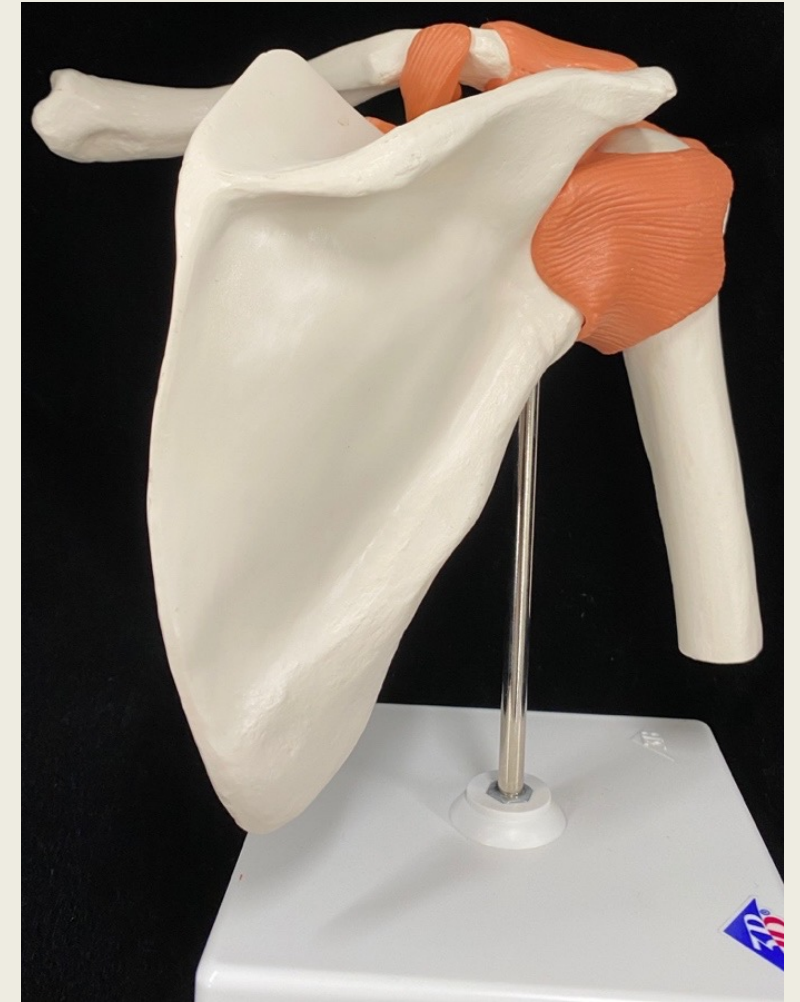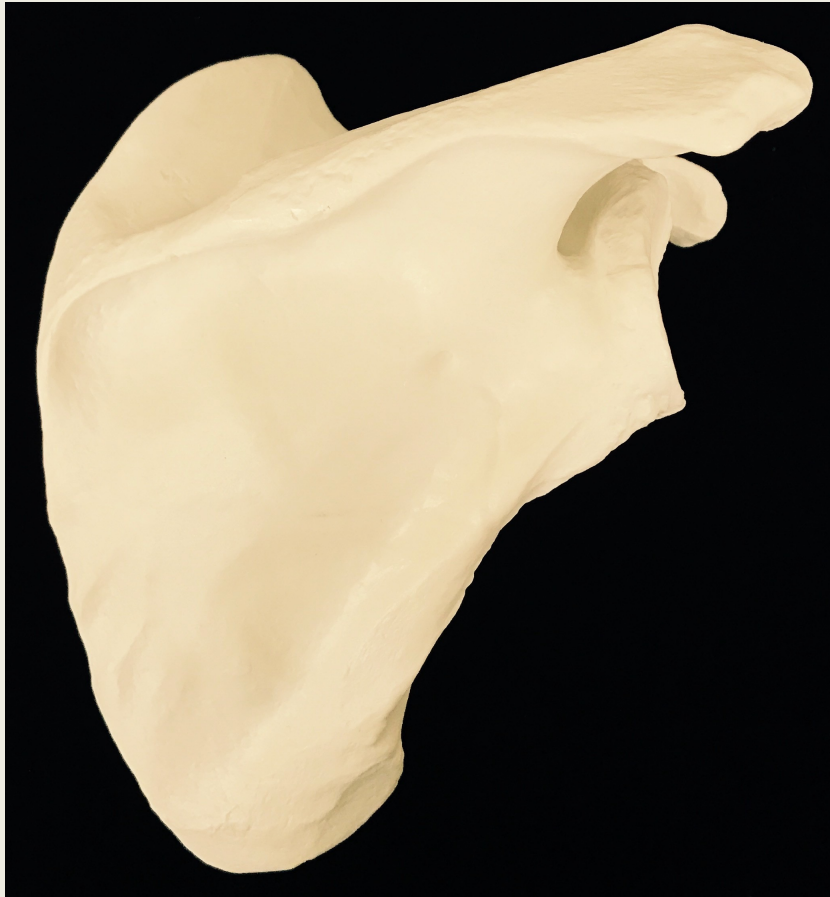
# Video Recording Links for Upper Limb

- [Module 6 Exercise 12 Video Scapula](#)
- [Module 6 Exercise 12 Video Clavicle](#)
- [Module 6 Exercise 15 Video Humerus](#)
- [Module 6 Exercise 15 Video Ulna](#)
- [Module 6 Exercise 15 Video Radius](#)
- [Module 6 Elbow joint video](#)
- [Module 6 Exercise 13 Video Wrist, Hand and Digits](#)

# Pelvic Girdle

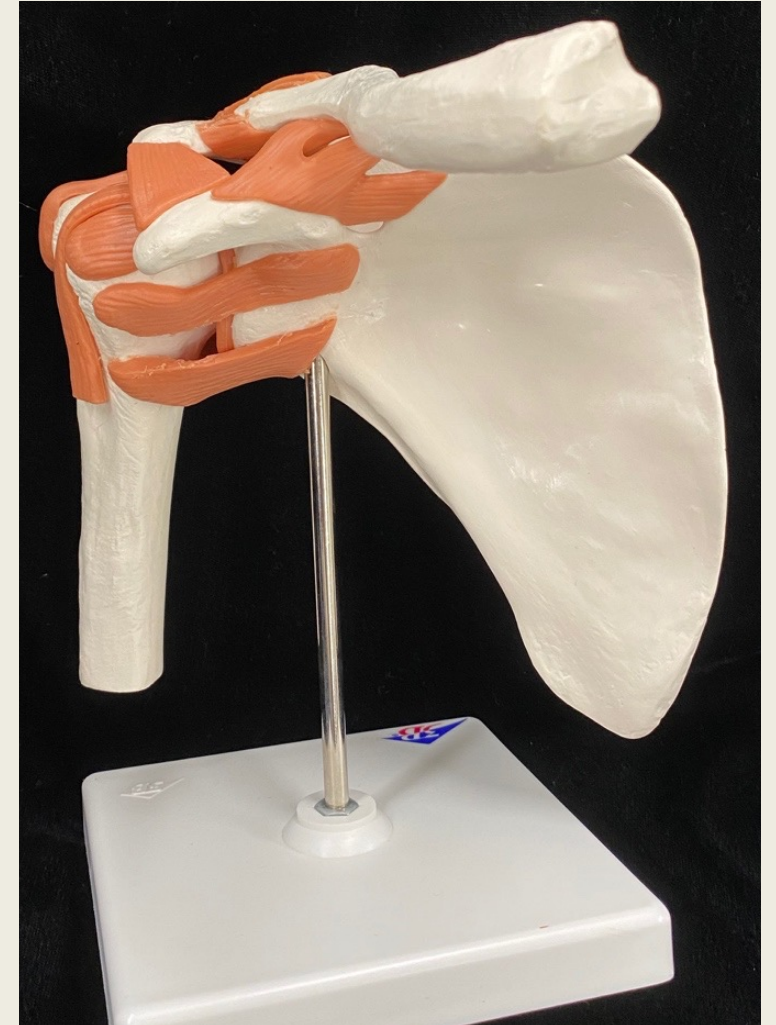
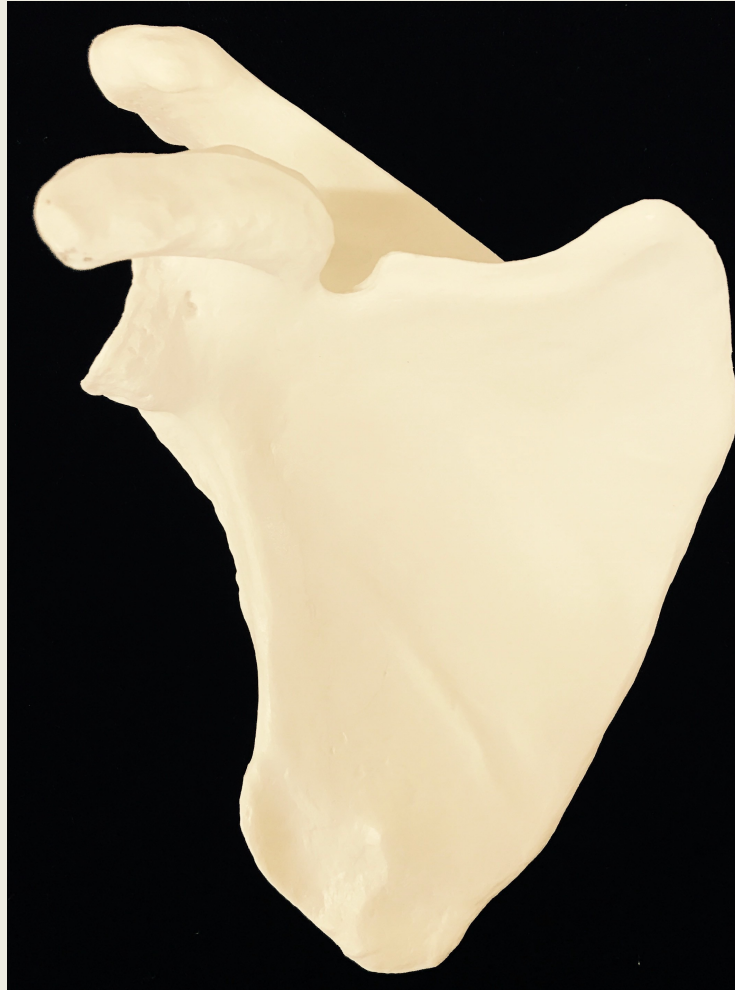Bone	Bone Features
Scapula	<ul style="list-style-type: none"><li>• acromion</li><li>• spine</li><li>• coracoid process</li><li>• glenoid fossa/glenoid cavity</li><li>• supraspinous fossa</li><li>• infraspinous fossa</li><li>• subscapular fossa</li></ul>
Clavicle	<ul style="list-style-type: none"><li>• sternal end</li><li>• acromial end</li><li>• conoid tubercle</li></ul>

# Pectoral Girdle posterior view

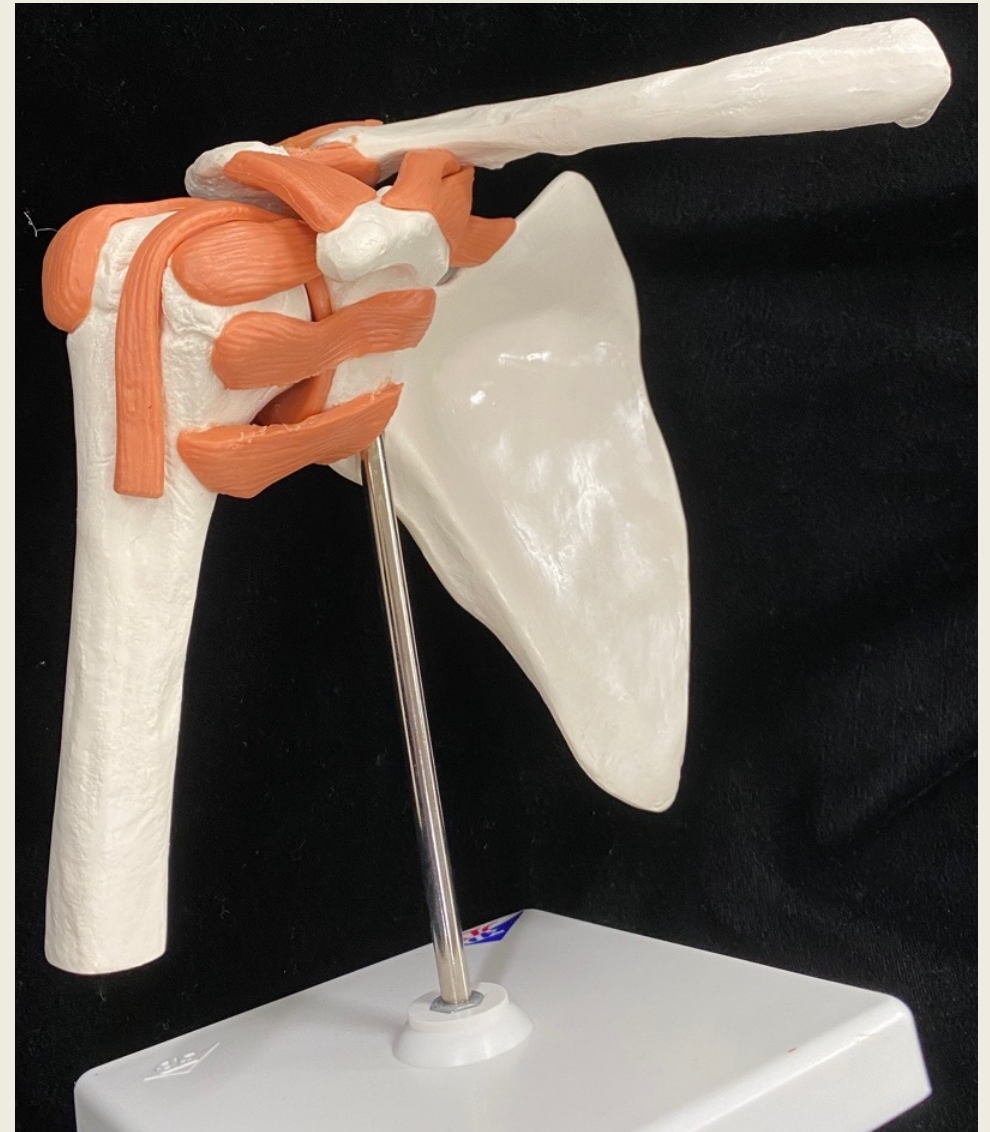




# Pectoral Girdle anterior view

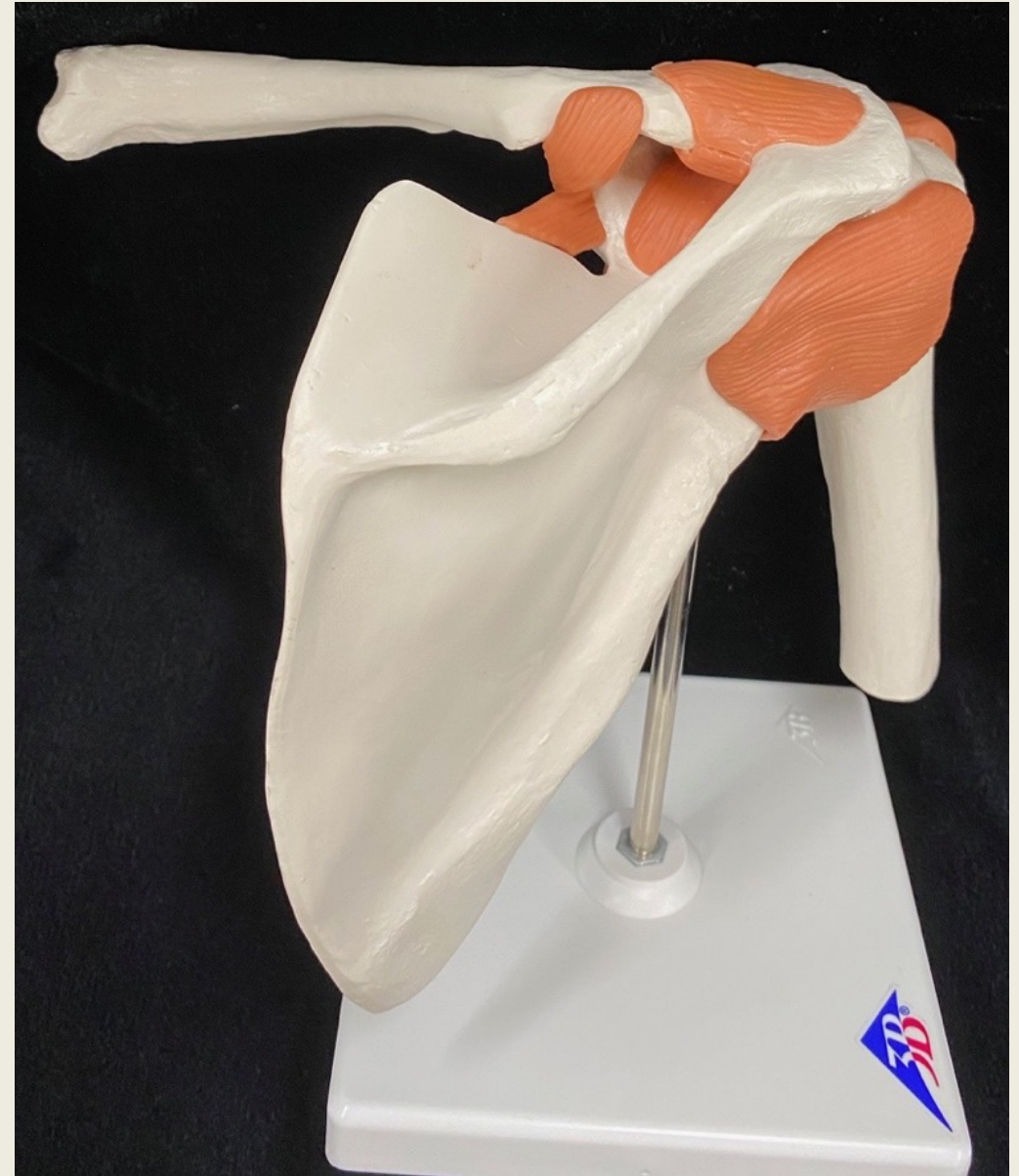

# Pectoral Girdle anterolateral view

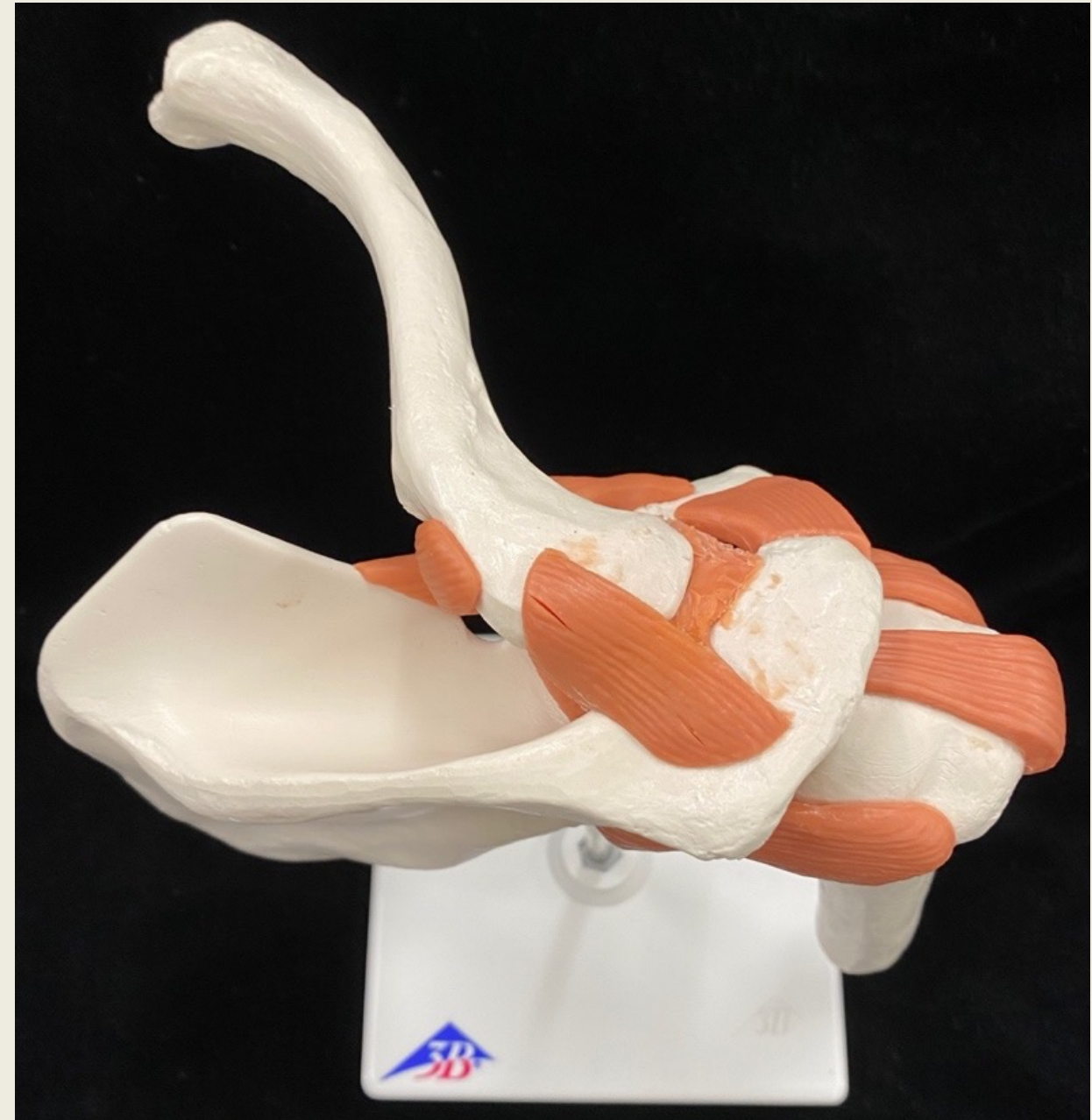



# Pectoral Girdle posteromedial view



# Pectoral Girdle superior view

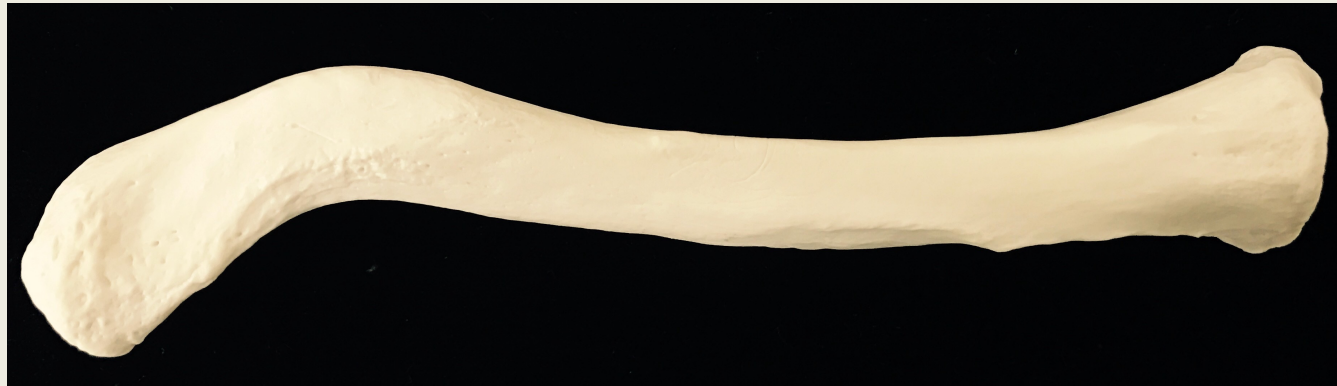



# Pectoral Girdle medial view



# Clavicle superior view

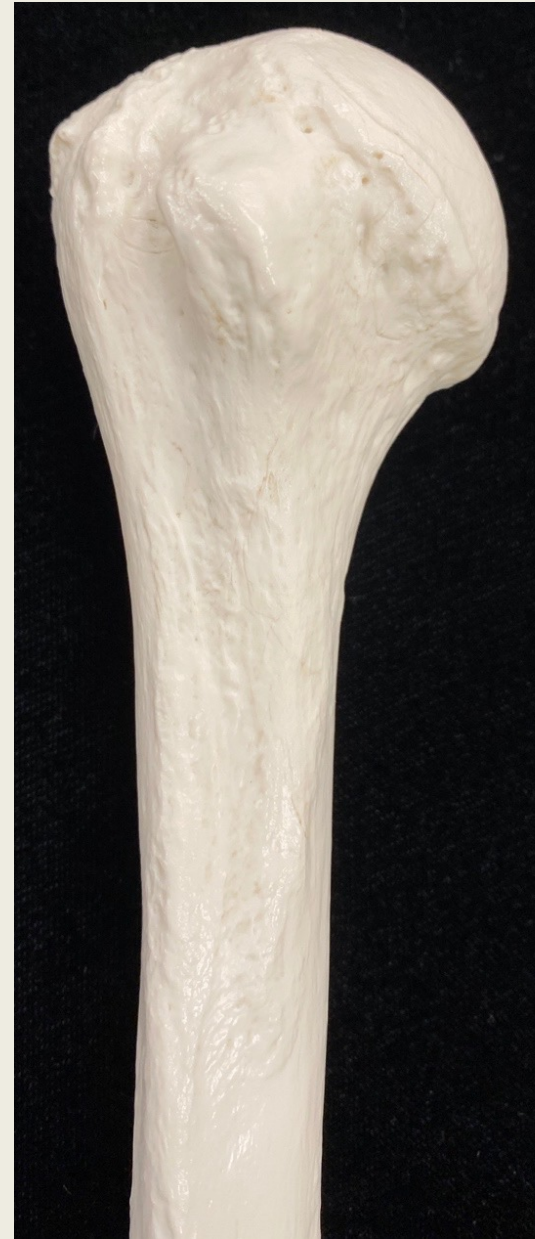
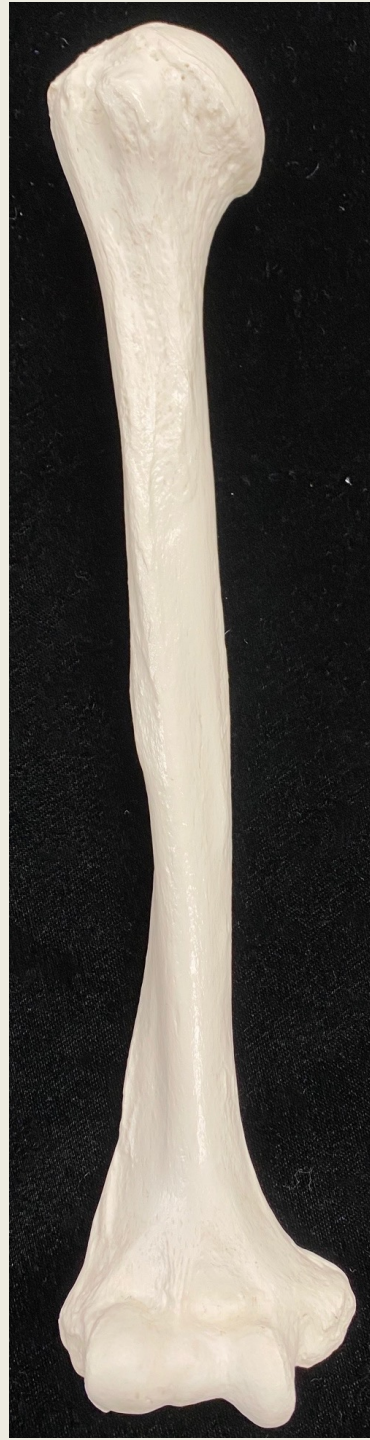


# Arm

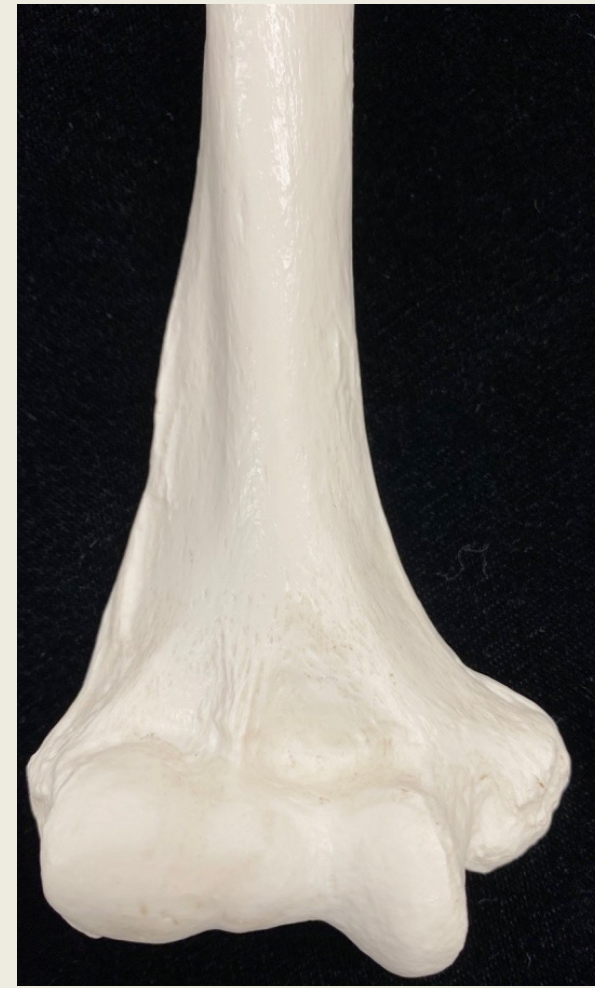Bone	Bone Feature
Humerus	<ul style="list-style-type: none"><li>• head</li><li>• anatomical neck</li><li>• surgical neck</li><li>• greater tubercle</li><li>• lesser tubercle</li><li>• intertubercular groove/bicipital groove</li><li>• deltoid tuberosity</li><li>• lateral epicondyle</li><li>• medial epicondyle</li><li>• capitulum</li><li>• trochlea</li><li>• olecranon fossa</li><li>• coronoid fossa</li><li>• radial fossa</li></ul>

# Humerus anterior view



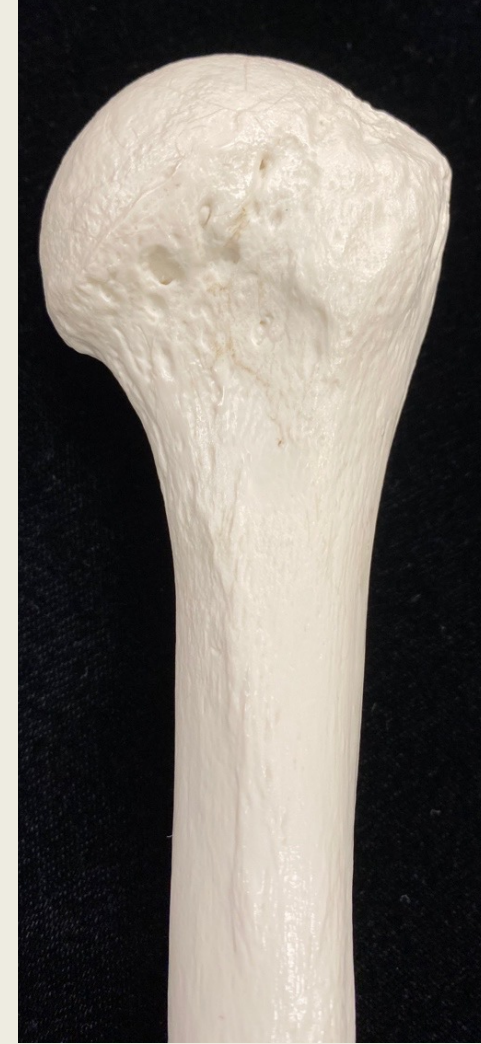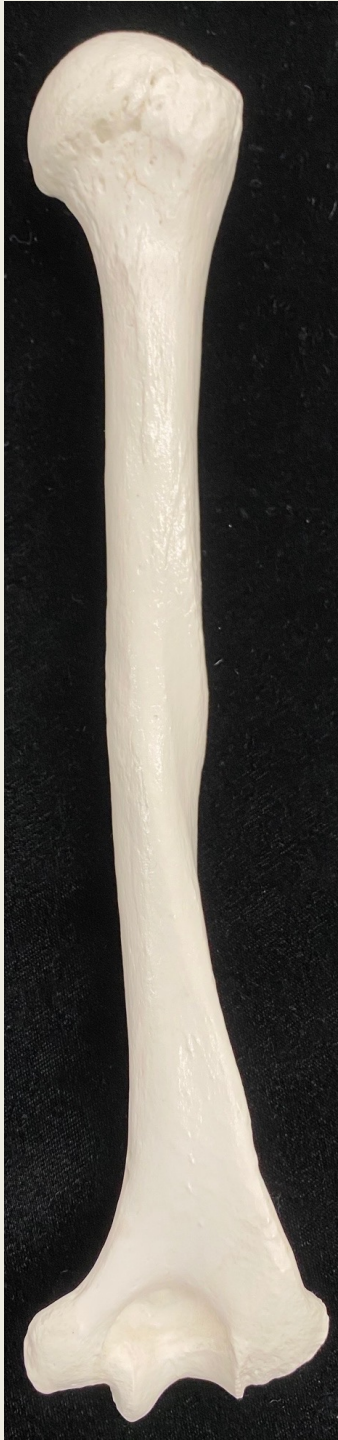Proximal End

Distal End



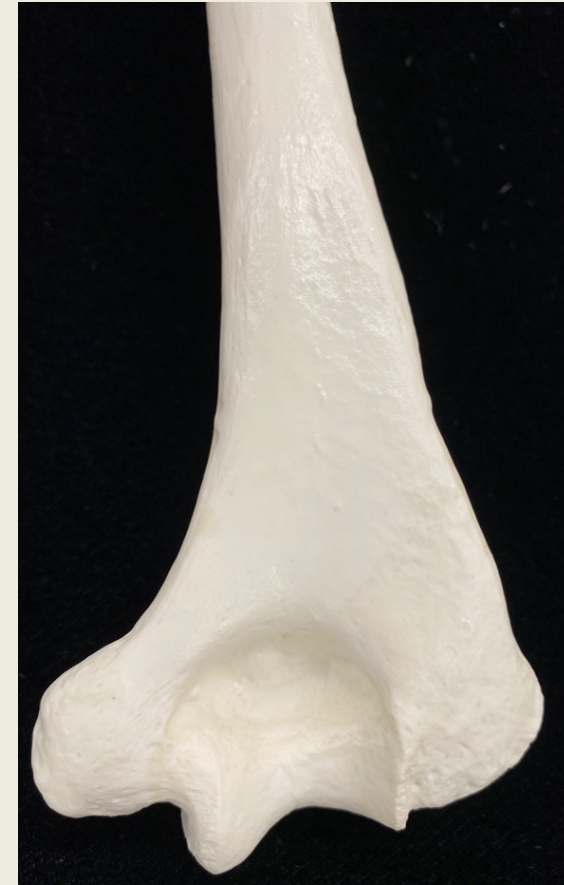

# Humerus posterior view

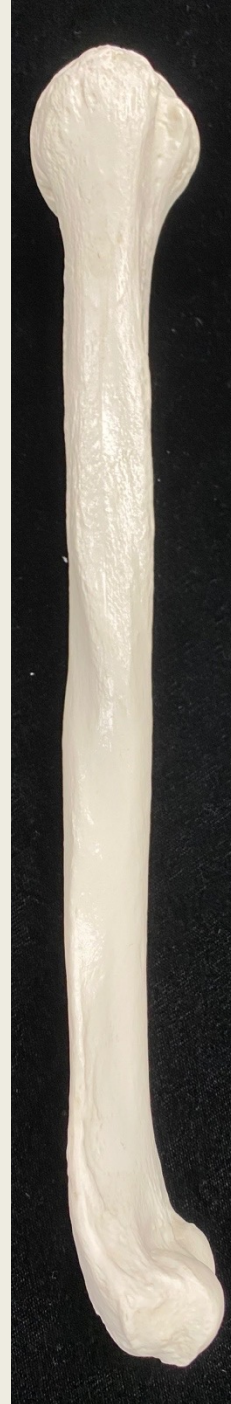

Proximal End

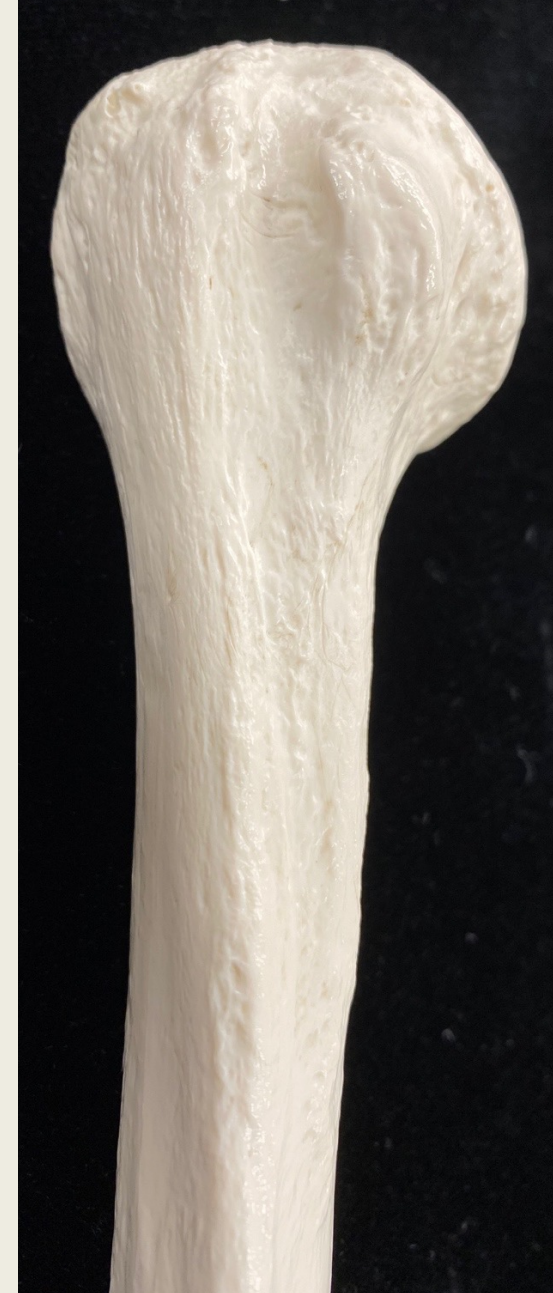Distal End



# Humerus lateral view anterolateral view



Proximal End  
Lateral View



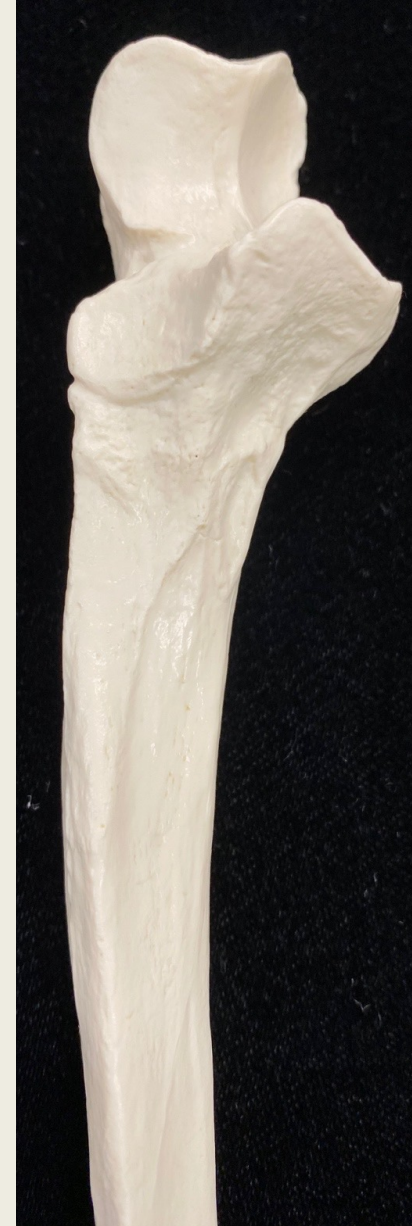Proximal End  
Anterolateral View

# Forearm

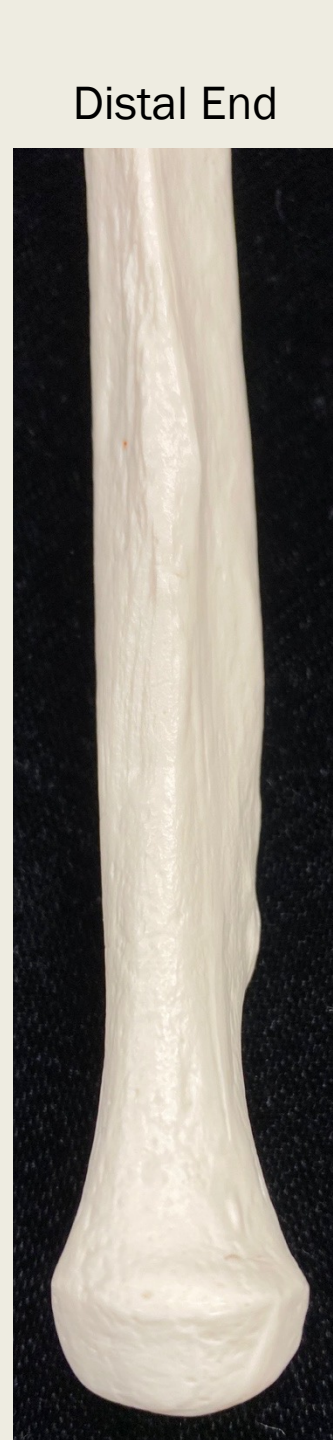Bone	Bone Features
Radius	<ul style="list-style-type: none"><li>• head</li><li>• radial tuberosity</li><li>• ulnar notch</li><li>• styloid process</li></ul>
Ulna	<ul style="list-style-type: none"><li>• head</li><li>• styloid process</li><li>• olecranon</li><li>• trochlear notch</li><li>• coronoid process</li><li>• radial notch</li></ul>



# Ulna lateral view

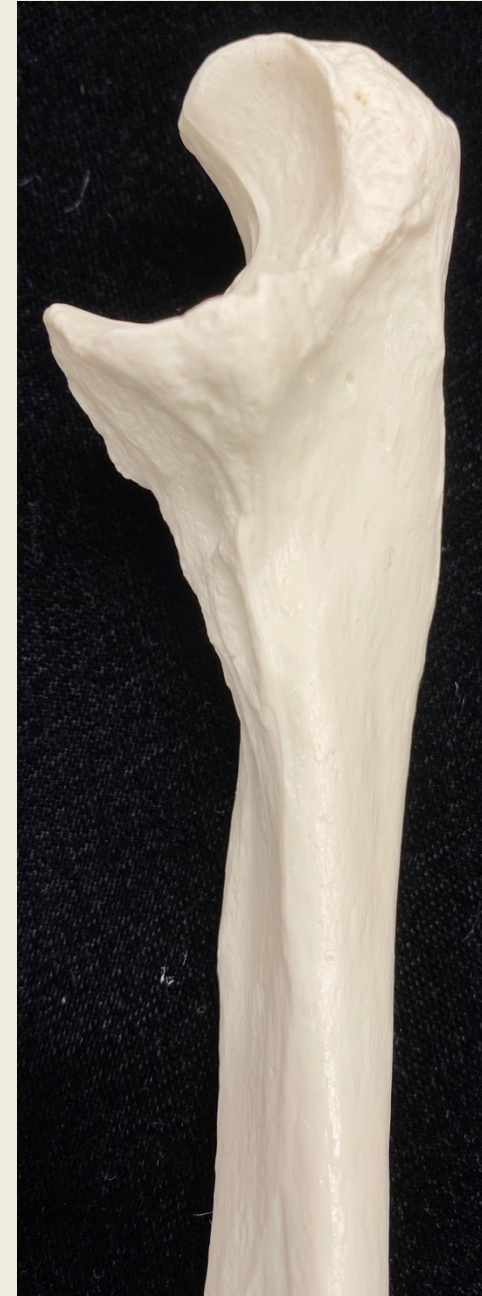

Proximal End



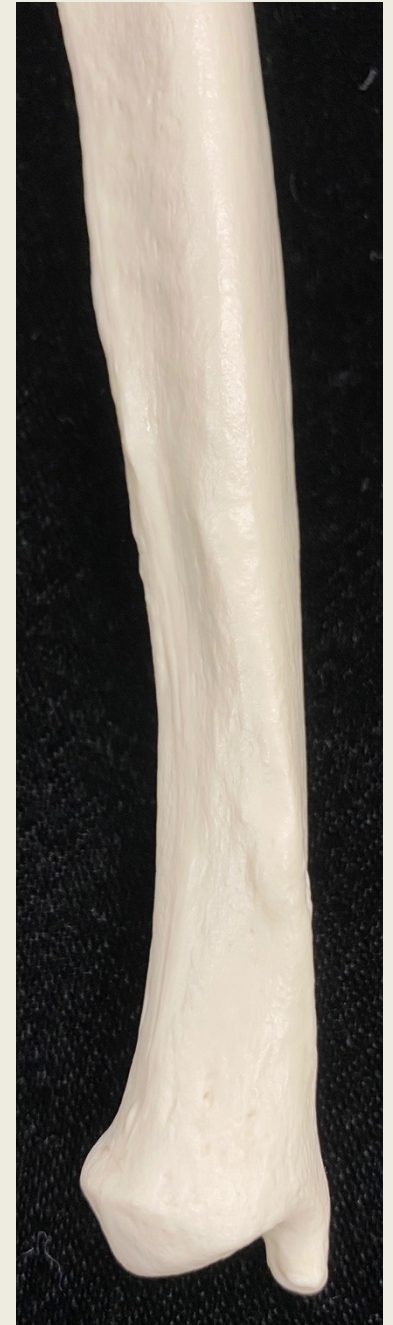Distal End

# Ulna medial view



Proximal End

Distal End





# Ulna posterior view



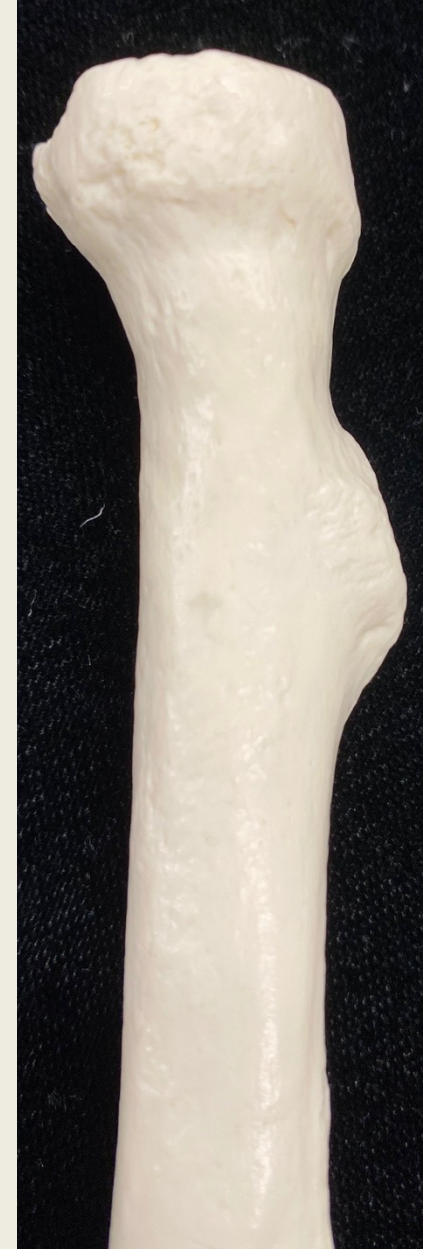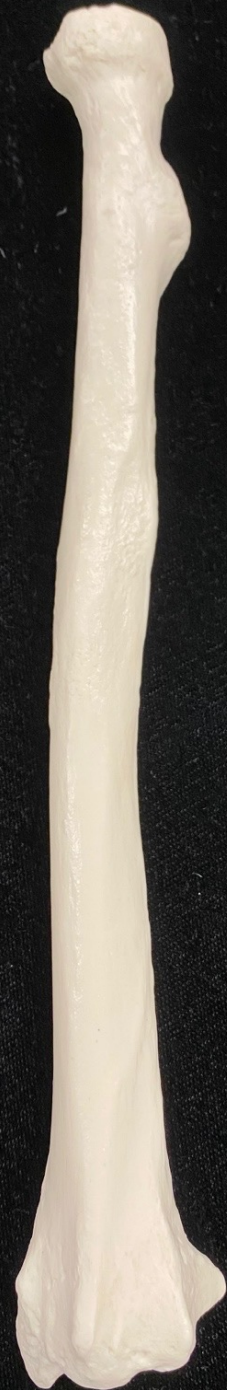Proximal End



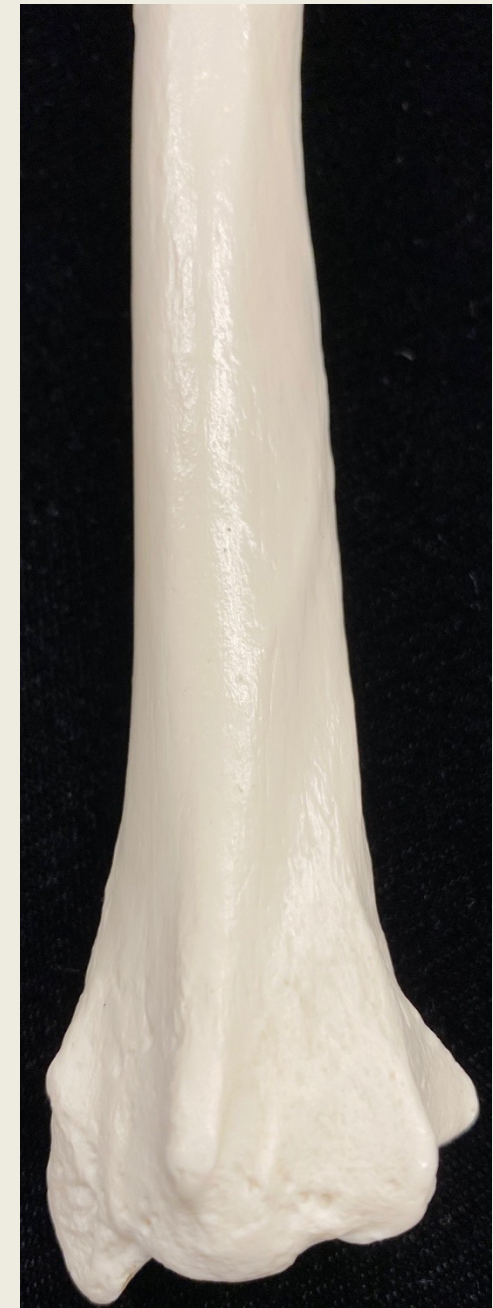Distal End



# Radius anterior view

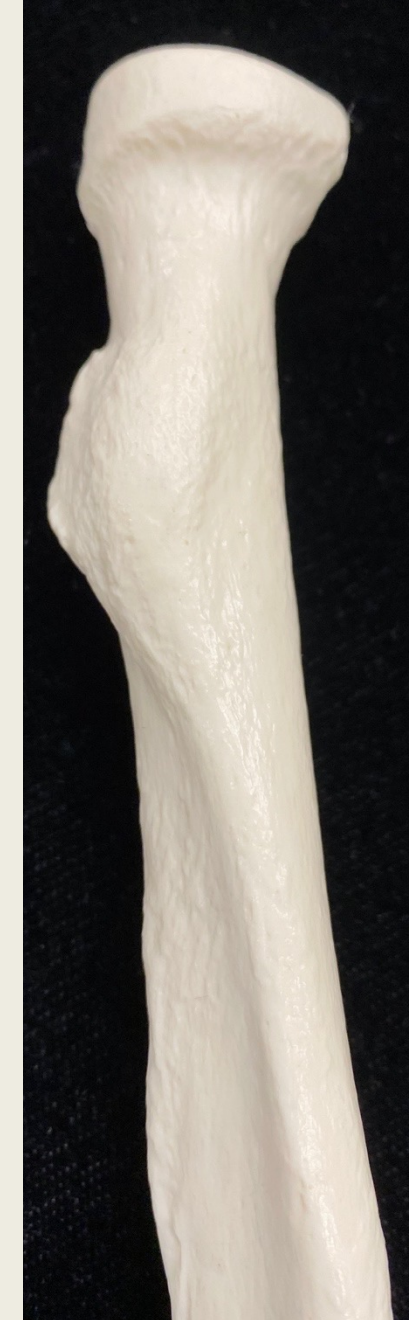

Proximal End



Distal End

# Radius posterior view



Proximal End

Distal End



# Wrist and Digits

Bone	Mnemonic:
<b>Carpals</b> <ul style="list-style-type: none"><li>• Scaphoid</li><li>• Lunate</li><li>• Triquetrum</li><li>• Pisiform</li><li>• Trapezium</li><li>• Trapezoid</li><li>• Capitate</li><li>• Hamate</li></ul>	<u>S</u> am <u>L</u> ikes <u>T</u> o <u>P</u> ush <u>T</u> he <u>T</u> oy <u>C</u> ar <u>H</u> ard <u>S</u> ome <u>L</u> overs <u>T</u> ry <u>P</u> ositions <u>T</u> hat <u>T</u> hey <u>C</u> an't <u>H</u> andle  <u>S</u> caphoid, <u>L</u> unate, <u>T</u> riquetrum, <u>P</u> isiform <u>T</u> rapezium, <u>T</u> rapezoid, <u>C</u> apitate, <u>H</u> amate
<b>Hand and digits</b> <ul style="list-style-type: none"><li>• Metacarpals (I-V)</li><li>• Phalange<ul style="list-style-type: none"><li>○ Proximal phalanx</li><li>○ Middle phalanx</li><li>○ Distal phalanx</li></ul></li><li>• Pollex</li></ul>	



# Wrist and Digits

## anterior and posterior views

